

REVIEW ARTICLE

The wide clinical spectrum of nocturnal frontal lobe epilepsy

Federica Provini, Giuseppe Plazzi, Pasquale Montagna and Elio Lugaresi

Institute of Clinical Neurology, University of Bologna, Bologna, Italy

Nocturnal frontal lobe epilepsy (NFLE) has become clinically relevant in recent years. NFLE represents a spectrum of clinical manifestations, ranging from brief, stereotyped, sudden arousals, often recurring several times per night, sometimes with a quasi-periodic pattern, to more complex dystonic–dyskinetic seizures and to prolonged “somnambulant” behaviour. Episodes of increasing intensity have been labelled as paroxysmal arousal (PA), nocturnal paroxysmal dystonia (NPD) and episodic nocturnal wandering (ENW).

NFLE affects both sexes with a higher prevalence for men, is frequently cryptogenetic and displays a strong familial trait for parasomnias and epilepsy (NFLE). Seizures appear more frequently between 14 and 20 years of age, but can affect any age and tend to increase in frequency during life. Interictal and ictal scalp electroencephalography (EEG) are often normal, the use of sphenoidal leads may be helpful. Carbamazepine taken at night is often effective at low doses, but a third of the patients are resistant to anti-epileptic drugs (AED) treatment. A familial form, characterized by an autosomal dominant transmission, has also been described. Autosomal dominant nocturnal frontal lobe epilepsy is a genetic variant of NFLE, in itself both clinically and biologically heterogeneous.

NFLE should be suspected in the presence of frequent stereotyped paroxysmal nocturnal motor events arising or persisting into adulthood. Videopolysomnography is mandatory to confirm the diagnosis.

© 2000 Harcourt Publishers Ltd

Key words: nocturnal frontal lobe epilepsy, paroxysmal arousal, nocturnal paroxysmal dystonia, episodic nocturnal wandering, parasomnias.

Introduction

In 1977 Pedley and Guilleminault [1] reported some cases of episodic nocturnal wandering (ENW) with inconclusive electroencephalography (EEG) recordings, which, because of the bizarre complex motor pattern and the positive response to antiepileptic treatment, they considered epileptic in nature. Their hypothesis was however disputed [2,3]. Recently we demonstrated that agitated somnambulant episodes similar to those previously described are indeed associated with ictal epileptic discharges [4].

In 1981, we labelled dystonic–dyskinetic or ballistic attacks arising from non-rapid eye

Correspondence to be addressed to: Federica Provini, MD, Istituto di Clinica Neurologica, Via Ugo Foscolo 7, 40123 Bologna, Italy. Fax: +39 51 6442165; E-mail: elugares@neuro.unibo.it

movement (NREM) sleep as hypnogenic or nocturnal paroxysmal dystonia (NPD) [5]. We hypothesized an epileptic origin on the basis of the short duration (less than 1 min) of the attacks, the stereotypic motor pattern and the response to anti-epileptic drugs (AED), but the absence of epileptic EEG abnormalities and the bizarre motor pattern could also suggest an undescribed movement disorder [5,6]. Later, with the aid of sphenoidal leads, we demonstrated clear-cut epileptic discharges during NPD in some patients [7] confirmed by later studies [8–10].

In 1986, Peled and Lavie [11] suspected that recurrent paroxysmal awakenings arising from NREM sleep and associated with daytime sleepiness were epileptic in origin. Some years later under the term paroxysmal arousal (PA) we identified sudden recurrent awakenings associated with stereotyped and abnormal movements. The epileptic origin of these episodes was confirmed by EEG in some of these cases [12]. Since PA, NPD and ENW often overlap, they were all speculated to be part of a spectrum of nocturnal frontal lobe epilepsy (NFLE) [12,13].

Several reports [13–15] suggested that NFLE can be familial. Berkovic's group showed that in some cases NFLE can be inherited as an autosomal dominant disorder (ADNFLE) [16,17]. Three mutations in the genes encoding for the neuronal nicotinic acetylcholine receptor (nAChR) localized on chromosome 20 have now been described, two in white families [18–21] and one in a Japanese family [22]; a new linkage to chromosome 15 has also been recently suggested [23]. The authors hypothesized that the different mutations may act on nAChR efficiency, causing a loss of function [24, 25]. This could also explain the peculiar sensitivity to carbamazepine [25]. Nevertheless, most ADNFLE families do not carry the described mutations [26–28] and the involvement of the nAChR in all the ADNFLE kindreds is still an hypothesis.

We recently described a large population of NFLE patients who underwent one or more polysomnographic recordings under audiovisual control, over a period of 20 years [29].

Clinical features

The high male prevalence (7:3 in our study) of NFLE is not shared by other partial epilepsies, but it is the rule in some sleep-related non-epileptic paroxysmal motor disorders such as the REM sleep behaviour disorders, in which it is even higher (9:1). The mean age at onset during adolescence (14 ± 10 years), also in familial forms of NFLE [17], is typical of other partial epilepsies [30]. This, together with the wide age range (between 1 and 64 years of age), also shared by familial NFLE [31, 32], probably reflects a polymorphic aetiology.

Neurological examination is almost always normal. A few cases present positive personal antecedents (birth anoxia, febrile convulsions, head injury). These general clinical features are not different in the ADNFLE series [17, 32].

Neuroradiological findings

A minority of cases present focal brain computed tomography (CT) and/or magnetic resonance imaging (MRI) abnormalities. Brain MRI is normal in ADNFLE patients [32], but in two patients presenting unilateral frontal EEG foci, a hypometabolism on

interictal PET and an ictal focal hyperperfusion on ictal single photon emission computed tomography (SPECT) [33] have been described.

Family and personal history and genetic findings

A quarter of our patients had a positive family history for epilepsy, but only a few families had two or more members with the same seizure type, consistent with a possible autosomal dominant pattern (ADNFLE). Our kindreds were phenotypically and genetically heterogeneous. In fact, a third of our cases (all the familial cases and other sporadic forms randomly selected) did not possess the two described mutations on the *CHRNA4* gene [27], and recently, one of our families showed a possible linkage to chromosome 15 [23].

Nearly half of our patients had a positive family history for one or more parasomnias, like sleep-talking, sleep-walking, primary enuresis, sleep terror, bruxism, head banging and REM-sleep behaviour disorder.

This frequency is much higher than that reported for large control populations in which the prevalence for sleep terrors and sleep-walking ranges from 1 to 6% of the entire population [34,35]. In addition, history-taking disclosed parasomnia in a third of cases. This could represent a bias or it could mean that epileptic seizures appearing during childhood were mistaken for night terrors and sleep-walking. If this is the case, the familial recurrence would be comparable with figures reported by others [36]. It is tempting to speculate, however, that both epileptic and non-epileptic nocturnal motor attacks share a common genetic predisposition.

Seizures

The mean seizure frequency reported by our patients is 20 ± 11 per month. More than half of the patients reported over 15 seizures per month and two-thirds of the patients reported more than one seizure per night. Stress, sleep deprivation and menstruation were triggering factors for seizure occurrence in a fifth of the cases. A third of the patients presented or referred an occasional secondarily generalized seizure and another third also had rare seizures during wakefulness.

NFLE comprises episodes varying in intensity and duration. Although seizure patterns differ, there is marked intraindividual stereotypy over the years. On the basis of our historical classification we distinguished three types of seizures: paroxysmal arousal (PA), nocturnal paroxysmal dystonia (NPD) and episodic nocturnal wanderings (ENW). Few patients presented only one type of seizure and different seizures tended to overlap in the same patient, the briefest episodes being the initial fragment of more prolonged attacks [37].

PA are abrupt frequently recurring arousals from NREM sleep with a stereotyped sequence of movements, lasting from 2–20 sec. The most common pattern (Fig. 1) consists of a sudden arousal during which patients raise their heads, sit on the bed with a frightened expression, look around and scream. They often present a dystonic posture of the upper or lower limbs. A minority of cases do not display the typical violent seizure pattern, but only slow bizarre asymmetric dystonic posture with choreo-athetoid, vermicular movements of the fingers or toes (Fig. 2). PA are the seizures most easily recorded, but, due to their short duration and scant impact on the patient's

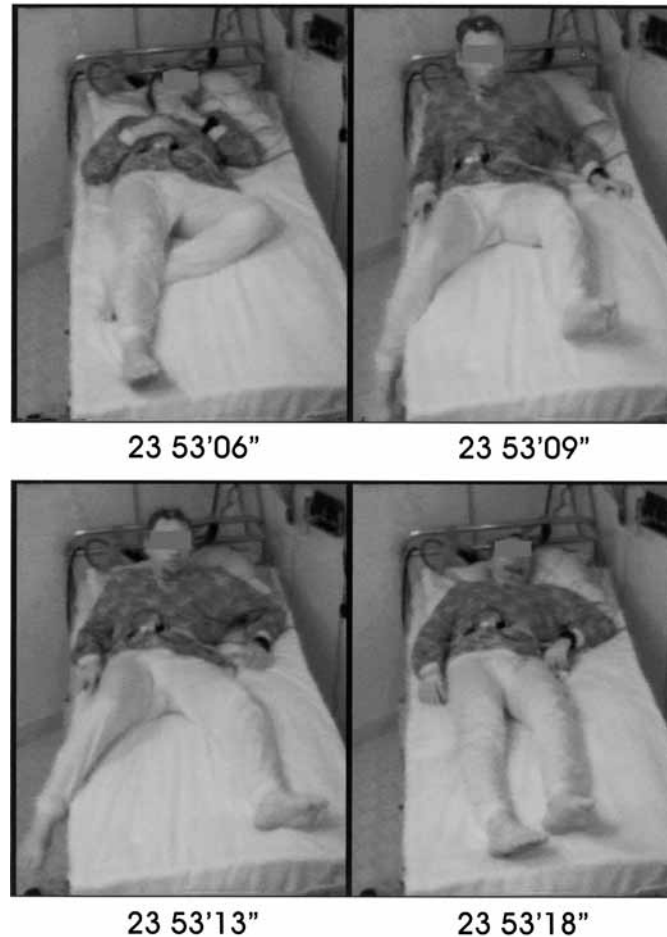


Figure 1. This PA seizure is characterized by an abrupt arousal during which patient raises his head and trunk with an astonished expression. The episode lasts 12 sec.

sleep, they are always underestimated or even not reported. Sometimes attacks are violent enough to wake the patient, but many patients remain unaware. Patients with PA alone are rare (under 10% in our series), but share some peculiar characteristics such as the lack of daytime seizures or personal antecedents and normal neuroradiological findings. Thus isolated PA represent a more benign disorder.

NPD is characterized by a sudden arousal associated with a complex sequence of movements, lasting from 25 to almost 100 sec (33 sec as a mean): patients move their legs and arms with cycling or kicking movements, rock their trunks and present a tonic asymmetric or dystonic posture of the limbs (Fig. 3). Clonic asymmetric jerks may also appear. A few cases are characterized by a violent ballistic pattern with flaying of the limbs.

ENWs are the longest episodes (lasting up to 3 min) during which patients jump out of bed, move around, talk unintelligibly or scream with a terrified expression (Fig. 4). Dystonic postures may involve the face, trunk and limbs. The agitated and violent motor behaviour may lead to severe injuries to the patient himself and is quite different from the calmer "physiological" motor pattern of walking in the sleep-walking patient.

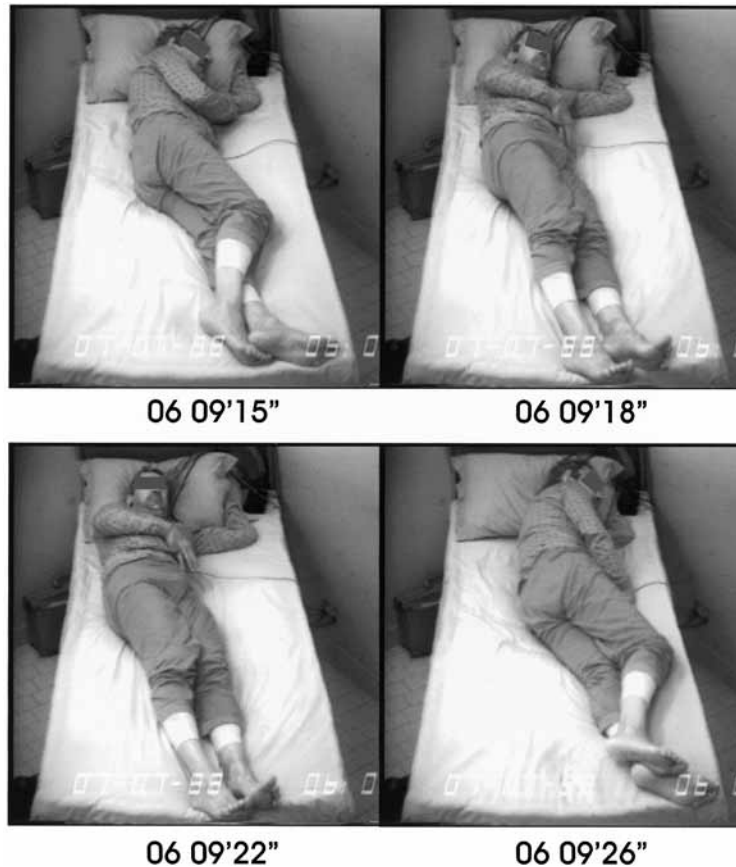


Figure 2. PA seizures may also display atypical but stereotyped patterns. In this case the patient shows a dystonic sustained posture of right arm, hand and leg with slow rotation of the body. The episode lasts 11 sec.

When patients have PA, NPD and ENW they present the same motor pattern at seizure onset indicating that there is a continuity between the different clinical manifestations (PA, NPD and ENW) [37] due to epileptic discharges spreading over the cortex [38].

Sleep complaints

The vast majority of patients, especially those with PAs alone, are not aware of their motor activity, but often report tiredness during the daytime, sleep fragmentation and a poor sleep quality. This has been noted before, daytime somnolence being the only symptom reported by patients with paroxysmal awakenings [11].

A marked improvement in daytime symptoms is widely reported by patients after AED introduction.



Figure 3. An NPD seizure. Patient abruptly raises his trunk with a dystonic posture of the right foot: he clutches the bed and violently rotates his legs. The seizure lasts 34 sec.

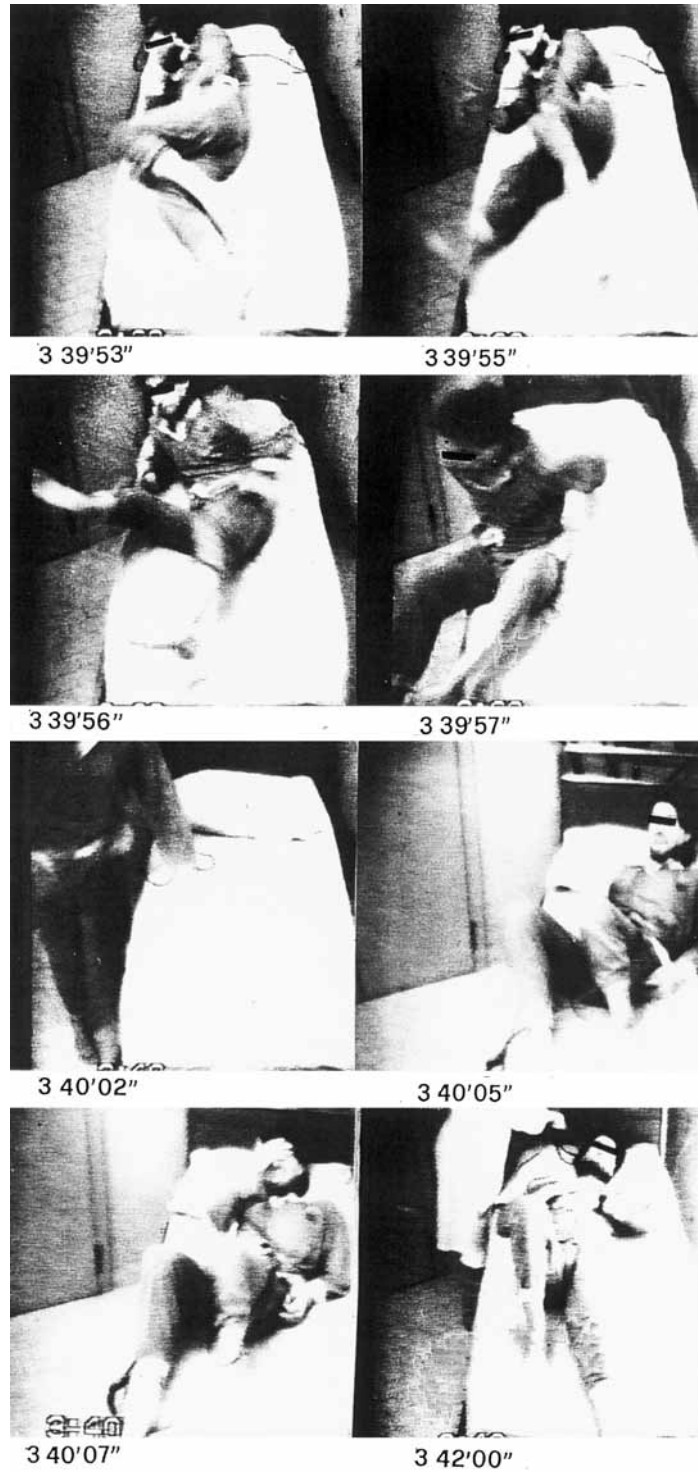


Figure 4. An ENW seizure. Patient abruptly divaricates and rotates his legs then suddenly jumps out of bed, moving around with violent ambulatory activity. The seizure lasts 127 sec.

Polygraphic findings

Virtually all attacks arise during NREM sleep, in particular during light sleep.

Wake and sleep interictal EEG tracings are normal in over half of the patients. An ictal modification of the EEG tracing is evident in half of the patients but very few EEG recordings display a clear-cut epileptic activity (spikes and spikes and waves). At onset, seizures are accompanied in nearly all patients by major autonomic manifestations involving heart rate, breathing, vasomotor tone and sympathetic skin response. EEG recording alone is not sufficient to establish a diagnosis of NFLE since without simultaneous video and polygraphic recordings of seizures the lack of EEG epileptic abnormalities is not sufficient to exclude NFLE.

In patients in whom interictal and ictal EEG are normal, special electrodes (zygomatic or sphenoidal) may be useful to detect epileptic abnormalities.

In a quarter of patients seizures of different intensity recurred periodically every 20 sec to 2 min during sleep, mostly during light sleep. A K-complex often coincides or immediately precedes the ictal EEG and autonomic modifications on the recordings suggesting that they are correlated. That the K-complexes may trigger the onset of NFLE seizures is suggested by the fact that NFLE tends to cluster with a quasi-periodic repetition at a rate similar to that of the K complexes and other periodic physiological phenomena during light sleep [39]. The clinical features of the seizures (sudden arousal, complex bizarre movements, marked autonomic changes) could be caused by an electric discharge from the mesio-orbital cortex impinging on the limbic subcortical circuits (basal forebrain, ventral striatum, visceral thalamus) which control sleep and wake, motor and autonomic functions. The involvement of the mesio-orbitofrontal cortex and the limbic subcortical circuits is consistent with the behaviour, the motor pattern and the complex autonomic manifestations (i.e. cardiovascular and respiratory changes).

Response to antiepileptic drugs and natural history

Carbamazepine remains the drug of choice for this type of attacks to control or significantly reduce seizures in most cases. A third of the cases, commonly patients with a high seizure frequency, are drug-resistant. NFLE does not show a tendency to spontaneous remission. In cases responding to treatment, withdrawal of the AED was often followed by a reappearance of seizures. This finding is similar to those of other variants of partial epilepsy, and conflicts with the concept that NFLE is always benign [36]. Since they occur only during the night, seizures are relatively well tolerated. In fact, some patients suffering from rare brief attacks (PA or NPD) decline therapy because they are not incapacitated.

Differential diagnosis

Most NFLE attacks occur during the night and lack clear-cut epileptic EEG abnormalities so that diagnosis remains a challenge. NFLE is often misdiagnosed as an arousal disorder, despite video-PSG recordings, especially in children [1–4,15,16]. The episodes differ from disorders of arousal because the latter tend to arise in childhood, usually between 4 and 6 years of age [40], and most cases resolve before the age of 18 [40,41].

Attack frequency also differs: disorders of arousal present a mean frequency of one isolated episode every 1–4 months [42], whereas NFLE seizures appear nightly and often cluster. Moreover, the motor pattern of the episode helps to differentiate NFLE from parasomnias. In fact NFLE has stereotypic, often “extrapyramidal” patterns (such as dystonic posturing, ballistic movements, tremor, choreo-athetosis) or even violent and agitated motor behaviour during ENW attacks. Video-PSG recording is mandatory to analyse and compare the semeiology of several attacks to confirm the intraindividual stereotypy of attacks.

REM sleep behaviour disorders, a REM sleep-related parasomnia can be readily differentiated from NFLE on the basis of later onset (around 60 years of age) and polymorphic behaviour with a dream associated with the typical polygraphic finding of REM sleep without atonia [43].

Nocturnal panic attacks also mimic NFLE, occurring with a sudden, often fearful, awakening from sleep with dramatic autonomic activation [44]. Other subjective complaints include tachycardia, constriction around the chest and neck [45] and a sensation of imminent death. Age at onset of panic attacks is in young adolescence (15–19 years) or middle age [46]; they are usually vividly recalled and seldom recur more than once per night. Their mean duration is usually prolonged, 24 min as a mean [46], but very brief episodes have also been described [47].

Differential diagnosis of NFLE must also include attacks described under the terms of NPD of intermediate and long duration [13,48,49]. NPD with intermediate duration (3–5 min) were observed in two children who had attacks triggered by arousal during sleep and by protracted exercise during wakefulness. Attacks were characterized by asynchronous jerks of the head, trunk and limbs resembling a puppet on strings, not associated with epileptic EEG activity, and did not respond to AED. This aspect coupled to the triggering effect of prolonged exercise suggests a paroxysmal motor disorder [49].

NPD with long-lasting (2–50 min) dystonic–dyskinetic attacks, arising from light sleep, recurring several times per night and resistant to AED were observed in two patients. One of them developed Huntington’s disease 20 years after onset of the nocturnal attacks. The long duration of the attacks, the inefficacy of anticonvulsants and the link with Huntington’s disease in one patient suggests a basal ganglia involvement [6,48].

Conclusion

NFLE accounts for 13% of our PSG recordings for nocturnal motor disorders run in our laboratory. Its clinical relevance has been and is still underestimated and many cases, especially in children, are misdiagnosed as having arousal disorders.

NFLE should always be suspected when paroxysmal nocturnal motor events arise or persist into adulthood and recur several times during the same night. Video-PSG recordings, showing stereotyped abnormal movements during attacks, are always mandatory to confirm the diagnosis. NFLE is only apparently benign, many patients being resistant to AED therapy, but the social impact of seizures is limited since they are confined to sleep.

ADNFLE is a genetic variant of NFLE, in itself both clinically and biologically heterogeneous. The clinical and semeiological features of the attacks, mimicking the orbito-frontal seizures originally described by Tharp [50] and then detailed by Wada

[51] and Williamson [52], the EEG findings consistent with a deep frontal lobe foci, and the occasional cases with lesions confined to the frontal brain areas offer evidence that the epileptogenic focus is located in the mesio-orbital frontal cortex. This cortical region represents the highest integrative level of the limbic circuits acting, in parallel with better known neocortical systems, as a motor control system with a strategic role in sleep–wake regulation and control of body homeostasis [53].

Acknowledgements

We thank Stefano Vandi and Nino Bertozzi for their contribution to the statistical analysis, Carlo Grassi for photographic assistance, Elena Zoni and Alessandra Laffi for technical assistance in preparing the manuscript. Supported by MURST grant 40% 1997.

Practice Points

1. NFLE must be distinguished from arousal disorders in children.
2. NFLE should be suspected when stereotyped paroxysmal agitated nocturnal motor behaviour recurs many times a night or month.
3. NFLE should be suspected when onset occurs or persists into adulthood.
4. EEG without epileptic abnormalities does not exclude NFLE.
5. NFLE patients respond to antiepileptic drugs, especially carbamazepine.
6. Video-EEG recording of the episodes is mandatory.

Research Agenda

1. The real incidence of NFLE and ADNFLE should be ascertained.
2. Long-term evolution throughout seizure semeiology should be monitored.
3. Neurophysiological ictal studies with deep electrodes and MEG studies should be undertaken.
4. Brain imaging and functional imaging studies are required.
5. Genetically defined families require phenotypic characterization.

References

- 1 Pedley TA, Guilleminault C. Episodic nocturnal wanderings responsive to anticonvulsant drug therapy. *Ann Neurol* 1977; **2**: 30–35.
- 2 Maselli RA, Rosemberg RS, Spire JP. Episodic nocturnal wandering responsive to anti-convulsant drug therapy. *Ann Neurol* 1988; **2**: 30–35.
- 3 Oswald J. Episodic nocturnal wandering. *Sleep* 1989; **12**: 186–187.
- 4 Plazzi G, Tinuper P, Montagna P *et al.* Epileptic nocturnal wanderings. *Sleep* 1995; **18**: 749–756.
- 5 Lugaesi E, Cirignotta F. Hypnogenic paroxysmal dystonia; epileptic seizures or a new syndrome? *Sleep* 1981; **4**: 129–138.
- 6 Lugaesi E, Cirignotta F, Montagna P. Nocturnal paroxysmal dystonia. *J Neurol Neurosurg Psychiatry* 1986; **49**: 375–380.
- 7 Tinuper P, Cerullo A, Cirignotta F *et al.* Nocturnal paroxysmal dystonia with short-lasting attacks: three cases with evidence for an epileptic frontal lobe origin of seizure. *Epilepsia* 1990; **31**: 549–556.

- 8 Meierkord H, Fish DR, Smith SJM *et al.* Is nocturnal paroxysmal dystonia a form of frontal lobe epilepsy? *Mov Disord* 1992; **7**: 38–42.
- 9 Hirsh E, Sellal F, Maton B *et al.* Nocturnal paroxysmal dystonia: a clinical form of focal epilepsy. *Neurophysiol Clin* 1994; **24**: 207–217.
- 10 Oldani A, Zucconi M, Ferini-Strambi L *et al.* Autosomal dominant nocturnal frontal lobe epilepsy: electroclinical picture. *Epilepsia* 1996; **37**: 964–976.
- 11 Peled R, Lavie P. Paroxysmal awakenings from sleep associated with excessive daytime somnolence: a form of nocturnal epilepsy. *Neurology* 1986; **36**: 95–98.
- 12 Montagna P, Sforza E, Tinuper P *et al.* Paroxysmal arousals during sleep. *Neurology* 1990; **40**: 1063–1066.
- 13 Montagna P. Nocturnal paroxysmal dystonia and nocturnal wandering. *Neurology* 1992; **42** (Suppl. 6): 61–67.
- 14 Lee BI, Lesser RP, Pippenger CE *et al.* Familial paroxysmal hypnogenic dystonia. *Neurology* 1985; **35**: 1357–1360.
- 15 Vigeveno F, Fusco L. Hypnic tonic postural seizures in healthy children provide evidence for a partial epileptic syndrome of frontal lobe region. *Epilepsia* 1993; **39**: 110–119.
- 16 Scheffer IE, Kailash PB, Lopes-Cendes I *et al.* Autosomal dominant frontal lobe epilepsy misdiagnosed as sleep disorder. *Lancet* 1994; **343**: 515–517.
- 17 Scheffer IE, Bhatia KP, Lopes-Cendes I *et al.* Autosomal dominant nocturnal frontal lobe epilepsy. A distinctive clinical disorder. *Brain* 1995; **118**: 61–73.
- 18 Phillips HA, Scheffer IE, Berkovic SF *et al.* Localization of a gene for autosomal dominant nocturnal frontal lobe epilepsy to chromosome 20q13.2. *Nat Genet* 1995; **10**: 117–118.
- 19 Steinlein OK, Mulley JC, Propping P *et al.* A missense mutation in the neuronal nicotinic acetylcholine receptor (4 subunit is associated with autosomal dominant nocturnal frontal lobe epilepsy). *Nat Genet* 1995; **11**: 201–203.
- 20 Steinlein OK, Magnusson A, Stoodt J *et al.* An insertion mutation of the CHRNA4 gene in a family with autosomal dominant nocturnal frontal lobe epilepsy. *Hum Mol Genet* 1997; **6**: 943–947.
- 21 Saenz A, Galan J, Caloustian C *et al.* Autosomal dominant nocturnal frontal lobe epilepsy in a Spanish family with a Ser252Phe mutation in the CHRNA4 gene. *Arch Neurol* 1999; **56**: 1004–1009.
- 22 Hirose S, Iwata H, Akiyoshi H *et al.* A novel mutation of CHRNA4 responsible for autosomal dominant nocturnal frontal lobe epilepsy. *Neurology* 1999; **53**: 1749–1753.
- 23 Phillips HA, Scheffer IE, Crossland M *et al.* Autosomal dominant nocturnal frontal-lobe epilepsy: genetic heterogeneity and evidence for a second locus at 15q24. *Am J Hum Genet* 1998; **63**: 1108–1116.
- 24 Bertrand D. Neuronal nicotinic acetylcholine receptors: their properties and alterations in autosomal dominant nocturnal frontal lobe epilepsy. *Rev Neurol* 1999; **155**: 457–462.
- 25 Picard F, Bertrand S, Steinlein OK, Bertrand D. Mutated nicotinic receptors responsible for autosomal dominant nocturnal frontal lobe epilepsy are more sensitive to carbamazepine. *Epilepsia* 1999; **40**: 1198–1209.
- 26 Berkovic SF, Phillips HA, Scheffer IE *et al.* Genetic heterogeneity in autosomal dominant nocturnal frontal lobe epilepsy. *Epilepsia* 1995; **36** (Suppl. 4): 147.
- 27 Mochi M, Provini F, Plazzi G *et al.* Genetic heterogeneity in autosomal dominant nocturnal frontal lobe epilepsy. *It J Neurol Sci* 1997; **18**: 183.
- 28 Nakken KO, Magnusson A, Steinlein OK. Autosomal dominant nocturnal frontal lobe epilepsy: an electroclinical study of a Norwegian family with ten affected members. *Epilepsia* 1999; **40**: 88–92.
- 29 Provini F, Plazzi G, Tinuper P *et al.* Nocturnal frontal lobe epilepsy. A clinical and polygraphic overview of 100 consecutive cases. *Brain* 1999; **122**: 1017–1031.
- 30 Hauser WA. Incidence and prevalence. In: Engel J Jr, Pedley TA (eds) *Epilepsy: A Comprehensive Textbook*. Philadelphia: Lippincott-Raven Publishers, 1998, pp. 47–57.
- 31 Picard F, Chauvel P. L'épilepsie frontale nocturne autosomique dominante: le syndrome. *Rev Neurol* 1999; **155**: 445–449.
- 32 Oldani A, Zucconi M, Asselta R *et al.* Autosomal dominant nocturnal frontal lobe epilepsy. A video-polysomnographic and genetic appraisal of 40 patients and delineation of the epileptic syndrome. *Brain* 1998; **121**: 205–223.
- 33 Hayman M, Scheffer IE, Chinvarun Y *et al.* Autosomal dominant nocturnal frontal lobe

- epilepsy: demonstration of focal frontal onset and intrafamilial variation. *Neurology* 1997; **49**: 969–975.
- 34 Partinen M. Epidemiology of sleep disorders. In: Kryger MH, Roth T, Dement WC (eds) *Principles and Practice in Sleep Medicine*. Philadelphia: WB Saunders, 1994, pp. 437–452.
 - 35 Hublin C, Kaprio J, Partinen M et al. Prevalence and genetics of sleepwalking: a population-based twin study. *Neurology* 1997; **48**: 177–181.
 - 36 Oldani A, Zucconi M, Ferini-Strambi L et al. Nocturnal frontal lobe epilepsy: clinical and video-polysomnographical features. *Epilepsia* 1997; **38** (Suppl. 3): 154–155.
 - 37 Sforza E, Montagna P, Rinaldi R et al. Paroxysmal periodic motor attacks during sleep: clinical and polygraphic features. *Electroencephalogr Clin Neurophysiol* 1993; **86**: 161–166.
 - 38 Talairach J, Bancaud J, Geier S et al. The cingulate gyrus and human behaviour. *Electroencephalogr Clin Neurophysiol* 1973; **34**: 45–52.
 - 39 Lugaresi E, Coccagna G, Mantovani M et al. Some periodic phenomena arising during drowsiness and sleep in man. *Electroencephalogr Clin Neurophysiol* 1972; **32**: 701–705.
 - 40 Cirignotta F, Zucconi M, Mondini S et al. Enuresis, sleepwalking, and nightmares: an epidemiological survey in the Republic of San Marino. In: Guilleminault C, Lugaresi E (Eds) *Sleep/Wake Disorders: Natural History, Epidemiology, and Long Term Evolution*. New York: Raven Press, 1983, pp. 237–241.
 - 41 Rottersman W. Selectee and his complaints. *Am J Psychiatry* 1946; **103**: 79–86.
 - 42 Sours JA, Frumkin P, Indermill RR. Somnambulism. *Arch Gen Psychiatry* 1963; **9**: 400–413.
 - 43 Schenck CH, Bundlie SR, Patterson AL et al. Chronic behavioral disorders of human sleep: a new category of parasomnia. *Sleep* 1986; **9**: 293–308.
 - 44 Plazzi G, Montagna P, Provini F et al. Sudden arousals from slow-wave sleep and panic disorder. *Sleep* 1998; **21**: 548.
 - 45 Craske MG, Barlow DH. Nocturnal panic. *J Nerv Ment Dis* 1989; **177**: 160–167.
 - 46 Von Korff MR, Eaton W, Key PM. The epidemiology of panic attacks and panic disorders. Results of three community surveys. *Am J Epidemiol* 1985; **122**: 970–981.
 - 47 Dantendorfer K, Frey R, Maierhofer D et al. Sudden arousals from slow wave sleep and panic disorders: successful treatment with anticonvulsants—a case report. *Sleep* 1996; **19**: 744–746.
 - 48 Lugaresi E, Cirignotta F. Two variants of nocturnal paroxysmal dystonia with attacks of short and long duration. In: Degen R, Niedermeyer E (eds) *Epilepsy, Sleep and Sleep Deprivation*. Amsterdam: Elsevier, 1984, pp. 169–173.
 - 49 Montagna P, Cirignotta F, Giovanardi Rossi P et al. Dystonic attacks related to sleep and exercise. *Eur Neurol* 1992; **32**: 185–189.
 - 50 Tharp BR. Orbital frontal seizures: a unique electroencephalographic and clinical syndrome. *Epilepsia* 1972; **13**: 627–642.
 - 51 Wada JA, Purves SJ. Oral and bimanual-bipedal activity as ictal manifestations of frontal lobe epilepsy. *Epilepsia* 1984; **25**: 668.
 - 52 Williamson PD, Spencer DD, Spencer SS et al. Complex partial seizures of frontal lobe origin. *Ann Neurol* 1985; **18**: 497–504.
 - 53 Lugaresi E, Tobler I, Gambetti P et al. The pathophysiology of fatal familial insomnia. *Brain Pathol* 1998; **8**: 521–526.