Received: 15 March 2020 | Revised: 18 May 2020 | Accepted: 26 May 2020

DOI: 10.1111/epi.16582

BRIEF COMMUNICATION

Epilepsia

Defining the phenotype of *FHF1* developmental and epileptic encephalopathy

Marina Trivisano[1] | Alessandro Ferretti[1] | Elizabeth Bebin[2] | Linda Huh[3] | Gaetan Lesca[4,5] | Aleksandra Siekierska[6] | Ryo Takeguchi[7] | Maryline Carneiro[8] | Luca De Palma[1] | Ilaria Guella[3] | Kazuhiro Haginoya[9] | Ruo Ming Shi[10,11] | Atsuo Kikuchi[12] | Tomoko Kobayashi[13] | Julien Jung[4,5] | Lieven Lagae[14] | Mathieu Milh[8] | Marie L. Mathieu[8] | Berge A. Minassian[15] | Antonio Novelli[16] | Nicola Pietrafusa[1] | Eri Takeshita[17] | Marco Tartaglia[16] | Alessandra Terracciano[16] | Michelle L. Thompson[18] | Gregory M. Cooper[18] | Federico Vigevano[19] | Laurent Villard[20] | Nathalie Villeneuve[21] | Gunnar M. Buyse[6] | Michelle Demos[3] | Ingrid E. Scheffer[22] | Nicola Specchio[1]

[1]Rare and Complex Epilepsy Unit, Department of Neuroscience, Bambino Gesù Children's Hospital IRCCS, Member of European Reference Network EpiCARE, Rome, Italy

[2]Department of Pediatric Neurology, University of Alabama at Birmingham, Birmingham, AL, USA

[3]Division of Neurology, Department of Pediatrics, University of British Columbia and BC Children's Hospital, Vancouver, BC, Canada

[4]Service de Génétique, Hospices Civils de Lyon, Lyon, France

[5]Institut Neuromyogène, Equipe Métabolisme énergétique et développement neuronal, CNRS, UMR 5310, INSERM U1217, Université Lyon 1, Lyon, France

[6]Pediatric Neurology, University Hospitals Leuven, Leuven, Belgium

[7]Department of Pediatrics, Asahikawa Medical University, Asahikawa, Japan

[8]Department of Pediatric Neurology, Femme Mère Enfant Hospital, Hospices Civils de Lyon, Lyon, France

[9]Department of Pediatric Neurology, Miyagi Children's Hospital, Sendai, Japan

[10]Department of Pediatrics, Tohoku University Graduate School of Medicine, Sendai, Japan

[11]Department of Pediatrics, First Affiliated Hospital of Xi'an Jiaotong University, Xi'an, China

[12]Department of Pediatrics, Tohoku University Hospital, Sendai, Japan

[13]Division of Child Development, Department of Preventive Medicine and Epidemiology, Tohoku Medical Megabank Organization, Tohoku University, Sendai, Japan

[14]Department of Development and Regeneration, University Hospitals KU Leuven, Leuven, Belgium

[15]Department of Pediatrics, University of Texas Southwestern, Dallas, TX, USA

[16]Genetics and Rare Diseases Research Division, Bambino Gesù Children's Hospital IRCCS, Rome, Italy

[17]Department of Child Neurology, National Center Hospital, National Center of Neurology and Psychiatry, Tokyo, Japan

[18]Hudson Alpha Institute for Biotechnology, Huntsville, AL, USA

[19]Department of Neuroscience, Bambino Gesù Children's Hospital IRCCS, Member of European Reference Network EpiCARE, Rome, Italy

[20]Aix Marseille University, Inserm, MMG, Marseille, France

[21]Department of Pediatric Neurology, APHM, Hopital de la Timone, Marseille, France

[22]Austin Health, and Royal Children's Hospital, Florey and Murdoch Institutes, University of Melbourne, Melbourne, Australia

Marina Trivisano and Alessandro Ferretti contributed equally to this paper.

Correspondence
Nicola Specchio, MD, PhD, Department of Neuroscience, Bambino Gesù Children's Hospital, IRCCS, P.zza S. Onofrio 4, 00165 Rome, Italy.
Email: nicola.specchio@opbg.net

Abstract

Fibroblast growth-factor homologous factor (*FHF1*) gene variants have recently been associated with developmental and epileptic encephalopathy (DEE). *FHF1* encodes a cytosolic protein that modulates neuronal sodium channel gating. We aim to refine the electroclinical phenotypic spectrum of patients with pathogenic *FHF1* variants. We retrospectively collected clinical, genetic, neurophysiologic, and neuroimaging data of 17 patients with *FHF1*-DEE. Sixteen patients had recurrent heterozygous *FHF1* missense variants: 14 had the recurrent p.Arg114His variant and two had a novel likely pathogenic variant p.Gly112Ser. The p.Arg114His variant is associated with an earlier onset and more severe phenotype. One patient carried a chromosomal microduplication involving *FHF1*. Twelve patients carried a de novo variant, five (29.5%) inherited from parents with gonadic or somatic mosaicism. Seizure onset was between 1 day and 41 months; in 76.5% it was within 30 days. Tonic seizures were the most frequent seizure type. Twelve patients (70.6%) had drug-resistant epilepsy, 14 (82.3%) intellectual disability, and 11 (64.7%) behavioral disturbances. Brain magnetic resonance imaging (MRI) showed mild cerebral and/or cerebellar atrophy in nine patients (52.9%). Overall, our findings expand and refine the clinical, EEG, and imaging phenotype of patients with *FHF1*-DEE, which is characterized by early onset epilepsy with tonic seizures, associated with moderate to severe ID and psychiatric features.

KEYWORDS

developmental and epileptic encephalopathy, epilepsy, FGF12, FHF1, genetic, neonatal onset

1 | INTRODUCTION

Developmental and epileptic encephalopathies (DEEs) are clinically and genetically heterogeneous severe neurodevelopmental disorders[1]. DEEs often start in infancy or early childhood and are severe conditions characterized by multiple seizure types, frequent epileptiform activity on electroencephalography (EEG), and developmental slowing or regression[2]. To date, a genetic etiology can be identified in more than 30% of cases, 60%–80% for epilepsies with neonatal onset[3,4]. Most patients have de novo pathogenic variants in genes encoding neuronal ion channels or proteins involved in synaptic transmission, regulatory, and developmental functions[2].

Recently, de novo mutations in fibroblast growth-factor homologous factor 1 (*FHF1*) gene, encoding a voltage-gated sodium channel subunit (Nav1.6) binding protein, have been reported in patients with severe epilepsies[5-11]. Nevertheless, a definite clinical phenotype has not clearly emerged. The recurrent missense variants of *FHF1* generally occur mostly as a de novo event in these patients and have been demonstrated to lead to a gain-of-function of the voltage-gated sodium channel (Nav1.6), thus increasing neuronal excitability[9,11].

The aim of this study is to report a large series of patients with pathogenic *FHF1* variants, including patients already published and new ones, in order to further delineate the phenotypic spectrum of *FHF1*-DEE, inform management and prognosis, and identify genotype-phenotype correlation.

2 | METHODS

This is an international retrospective multicenter study. We ascertained patients with *FHF1*-related epilepsy from 14 epilepsy centers (Belgium, Canada, China, France, Italy, Japan, Poland, United Kingdom, and United States). Patients A-K and Q have been reported previously, and we obtained additional information on all cases[5-11]. Only the genetic variant has been reported for Patient L[12]. For each patient, the referring physician completed a detailed medical questionnaire including demographic data, *FHF1* variant, family history, age at epilepsy onset, seizure semiology and frequency, EEG features, neurological examination, comorbidities, brain imaging, and treatment. We reported all the collected data, and we correlated age at epilepsy onset, seizure semiology and status epilepticus occurrence, developmental delay, and MR

findings with the genotypes: p.Arg114His, c.334G>A, and *FHF1* microduplication.

The study was approved by the local institutional ethics committees. Written informed consent was obtained from all patients and parents or legal guardians. Epileptic seizures were classified according to the International League Against Epilepsy (ILAE) Classification[1,13].

3 | RESULTS

We ascertained 17 patients with *FHF1*-DEE, including 12 cases described previously. Median age at study was 8.7 ± 8.59 years (range 1 month-33 years); seven (41.2%) patients were female. All cases were sporadic except for two siblings (A, B). Clinical, EEG, neuroimaging, and genetic details are summarized in Table 1.

3.1 | FHF1 pathogenic variants (NM_021032.4)

Two heterozygous missense mutations were identified: three recurrent c.341G>A, p.(Arg114His) was present in 14 patients, whereas two unrelated patients had a novel missense variant: c.334G>A, p.(Gly112Ser) (P, Q). They were localized in the same protein domain. In silico predictions for the p.(Gly112Ser) variant were very similar to the recurrent p.(Arg114His): CADD = 28.3, Polyphen-2 = Pathogenic, Mutation Taster = Pathogenic, and SIFT = Tolerated. According to the standards and guidelines for the interpretation of sequence variants of the American College of Medical Genetics, this variant could be classified as likely pathogenic (PS2, PP3, PM2, PP5). It was absent from the gnomAD database of control individuals but had been reported once in ClinVAr as likely pathogenic in a patient with developmental and epileptic encephalopathy (RCV000626031.1).

In addition, one patient (I) carried a chromosomal microduplication including the whole *FHF1* gene (0.58-Mb gain, arr[hg19] 3q28q29 (191876978_192454675)x1). *FHF1* pathogenic variants were de novo in 12 patients. Five patients (29.5%) inherited the variant from a parent, unaffected or affected with a milder epilepsy phenotype, who had the variant present but with mosaicism with variant allele fractions 0 (germline mosaicism) to 52%. Patient J inherited the *FHF1* variant from his unaffected mother who had somatic mosaicism (blood leukocytes showed a variant allele fraction of 11.7%, 11/94 clones). Two patients inherited the variant from their affected parents: Patient O from his 23-year-old father, who had drug-resistant epilepsy since the age of 8 months, carrying a somatic mosaicism (blood leukocyte variant allele fraction of 7%, 10/1479 reads); and Patient P from his mother who had epilepsy during infancy (blood leukocyte variant allele fraction of 52%, 178/338 reads). In one family (A,B), paternal germline mosaicism was presumed based on the occurrence of one epileptic seizure when the father was 5-years-old (Table 1).

3.2 | Epilepsy

Seizure onset ranged from 1 day to 3 years 5 months. In 13 patients (76.5%), seizure onset was within 30 days. Tonic seizures were the most common seizure type (15/17, 88.2%), and were associated with autonomic signs such as apnea (5/15, 33.3%) and bradycardia (2/15, 13.3%). Fourteen patients developed additional seizures, including focal to bilateral tonic-clonic (n = 11), myoclonic (n = 2), atonic (n = 2), epileptic spasms (n = 2), absence (n = 1), and generalized tonic-clonic (n = 1) after the age of 3 years and 5 months. Status epilepticus (SE) occurred in 8 patients (47%). Seizure frequency was highly variable, from multiple per day to long seizure-free periods lasting up to several years (12 years for Patient J). Following ILAE classification,[1] eight patients had combined generalized and focal epilepsy, seven presented focal epilepsy, and two unknown epilepsy.

Twelve patients (70.6%) had drug-resistant epilepsy, whereas five (Patients F, G, O, P, Q) achieved good seizure control with different drug combinations. Drugs most commonly used were phenobarbital and phenytoin. Twelve patients were treated with phenytoin with a transient effect in six (A, B, D, F, I, K). Data on response to other drugs (phenobarbital, rufinamide, lamotrigine, carbamazepine, and vigabatrin) were not conclusive. Ketogenic diet and vagus nerve stimulation were beneficial in Patients N and D, respectively.

Two siblings (A,B) died at age 7 and 3.5 years from SE and unknown cause, respectively.

3.3 | EEG studies

At seizure onset, EEG was available in 13 patients: Background activity was slow in six (46.1%), discontinuous in two (15.4%), normal in four (30.8%), and one patient at onset had a suppression-burst pattern (7.7%). Nine patients (69.2%) had multifocal spikes, and two (15.4%) had focal spikes. Discontinuous and suppression-burst EEG patterns were seen between 2 and 7 days of life. During follow-up, 12 patients (70.6%) showed increased background slowing with marked suppression in one case (Patient J); 12 patients showed increased interictal focal or multifocal spikes. Four patients also had diffuse spike and wave discharges.

Ictal EEG studies were reported as focal (with rapid spread to bilateral regions) or generalized with low-voltage fast activity, followed by diffuse rhythmic spikes and postictal suppression (Figure 1).

TABLE 1 Summary of molecular, clinical, EEG, and neuroimaging features of all published and unpublished patients with *FHF1* developmental and epileptic encephalopathies

PATIENT ID	A	B	C	D	E	F	G	H	I	J	K	L	M	N	O	P	Q
Reference	Siekierska et al 2016	Siekierska et al 2016	Al-mehmadi et al 2016	Al-mehmadi et al 2016	Al-mehmadi et al 2016	Guella et al 2016	Guella I. et al 2016	Villeneuve et al 2017	Shi RM. et al 2017	Takeguchi R. et al 2018	Takeguchi R. et al 2018	Epilepsy Genetics Initiative, 2019 [a]phenotype unpublished	unpublished	unpublished	unpublished	unpublished	Paprocka et al 2019
Gender/Age at last observation/death (cause)	F/died age 7 y (SE)	M/died age 3 y 6 mo (unknown cause)	M/3 y	F/16 y	F/8 y	F/3 y 3 mo	F/15 y	M/9 y	M/15 y 1 mo	M/33 y 3 mo	M/2 y 6 mo	M/5 y 8 mo	F/1 mo	F/13 y	M/2 y 10 mo	M/4 y 2 mo	M/4 y 6 mo
FHF1 variant, inheritance	c.341G>A[a] presumed gonadal mosaicism	c.341G>A[a] presumed gonadal mosaicism	c.341G>A de novo	c.341G>A de novo	c.341G>A de novo	c.341G>A de novo	c.341G>A de novo	c.341G>A de novo	arr[hg19] 3q28q29 x1, 0.58-Mb gain, including FHF1 gene, de novo	c.341G>A[b] inherited, see legend	c.341G>A de novo	c.341G>A de novo	c.341G>A de novo	c.341G>A de novo	c.341G>A[c] inherited, see legend	c.334G>A[d] inherited, see legend	c.334G>A de novo
EPILEPSY																	
Epilepsy onset	14 d	28 d	2 d	42 d	2 d	2 d	2 d	1 d	3 y 5 mo	7 d	1 d	31 d	2 d	3 d	8 d	4 mo	4 mo
Seizure type	TS	TS	FTS, FBTCS	FTS, MS, FBTCS	FTS, FS	FTS	FS, FBTCS	AS, FS	GTCS, FS, FTS	TS, ES	FTS, FS, FBTCS	TS	FS FTS	A, FTS, FBTCS	FS, TS, FBTCS	TS, FBTCS	TS, MS, ES, FTS, FBTCS
Epilepsy Type	Combined generalized and focal epilepsy	Combined generalized and focal epilepsy	Focal epilepsy	Combined generalized and focal epilepsy	Focal epilepsy	Focal epilepsy	Focal epilepsy	Combined generalized and focal epilepsy	Combined generalized and focal epilepsy	Focal epilepsy	Focal epilepsy	Combined generalized and focal epilepsy	Focal epilepsy	Combined generalized and focal epilepsy	Unknown	Unknown	Combined generalized and focal epilepsy
SE (frequency)	frequent	infrequent	frequent	frequent	frequent	no	n.a.	n.a.	no	monthly	no	yes (twice)	no	frequent	yes (twice)	no	no
EEG																	
Interictal EEG	Slow BG, multifocal SW (onset)	Slow BG, multifocal SW (onset)	Slow BG, multifocal SW	Slow BG, multifocal SW	Slow BG, multifocal SW	Discontinuous, multifocal SW (onset); increase of diffuse/ multifocal SW; from 10 mo normal EEG (FU)	Slow BG left temporal SW (onset); slow BG and multifocal SW (FU)	Normal BG, multifocal spikes (onset); focal spikes (FU)	Slow BG, Frontal SW (onset); Slow BG, multifocal SW (FU)	Suppression burst (onset); slow BG with focal spikes (FU)	Slow BG, multifocal and diffuse SW (onset); slower BG multifocal SW (FU)	Normal BG, multifocal SW (onset); slow BG and multifocal SW (FU)	Discontinuous and multifocal SW (onset); slow BG with increase of diffuse/ multifocal SW	Slow BG, multifocal SW (onset); Slow BG and multifocal and diffuse SW (FU)	Normal BG multifocal SW (onset) Slow BG and posterior SW (FU)	Normal	Normal (onset); generalized and focal paroxysmal in temporal regions (FU)
Ictal EEG	Generalized onset (tonic seizure)	Generalized onset (tonic seizure)	Focal to bilateral t-c	n.a.	n.a.	Generalized onset	Generalized onset (tonic seizure)	Generalized onset (tonic seizure)	Generalized onset (AS, TS, GTCS) Focal seizures: R or L hemisphere	n.a.	Generalized onset. Seizure activity migrated from one region to another	Diffuse onset	n.a.	L hemisphere; R frontal/ frontotemporal	R central	n.a.	Generalized polyspikes, spike-SW complexes
TREATMENT																	
ASM	PB, VPA, PHT, GVG, TPM, CZP; PN	PB, VPA, PHT, GVG, TPM	LEV, PB, KD	PHT, PER, VNS	PHT, PRG, PER, VNS	PB, LEV, TPM, PHT, CBZ	PB, TPM, LTG, RUF	PB, GVG, CBZ, CLB, ESM, KD	PB, CLB, VPA, KBr, PHT, LEV, NZP	VPA, PB, PHT, CZP, AZA, PHT, GBP	PB, PN, CBZ, CLB, VPA, ZNS, LEV, KBr, PHT	PB, PHT, CBZ, LEV, RTG, VPA	PB, LEV, PN/ PLP, TPM, CBZ, PHT	PB, LEV, PHT, OXC, LCM, CLZ, PER, TPM, VNS, KD	VPA, CZP, LEV, GVG, CBZ, PN, PLP, PB, Folic Acid, Biotin	LEV, VPA, LTG	PB, CBZ, VPA, LEV, GVG, steroids, PHT

(Continues)

TABLE 1 (Continued)

PATIENT ID	A	B	C	D	E	F	G	H	I	J	K	L	M	N	O	P	Q
ASM efficacy	Resistant to ASMs; best response to PHT	Resistant to ASMs; best response to PHT	Resistant to ASMs	Resistant to ASMs; partially responsive to PHT and VNS	Resistant to ASMs	Responsive to PHT and CBZ	Responsive: to RUF and LTG,	Partially responsive to CBZ	Best response to high dose of PHT	Partially responsive to PHT, CZP and VPA	Best response to PHT and high dose of PB	Partially responsive to VPA	Resistant to ASMs	Resistant to ASMs	ASMs-responsive	ASMs-responsive	Best response to PB and PHT
DEVELOPMENT																	
ID	severe	severe	severe	severe	moderate	no	moderate	mild	severe	severe	severe	moderate	moderate	moderate	moderate	no	moderate
ASD and other disturbances	stereotypies, absent eye contact, acquired microcephaly	stereotypies, absent eye contact, acquired microcephaly	n.a.	n.a.	yes	no	yes	very tight	yes, stereotypies, absent eye contact	yes, stereotypies, absent eye contact	No, poor eye contact, congenital microcephaly	yes, stereotypies, absent eye contact	No, rapid mood swings, congenital microcephaly	yes, severe obsessive behavior	yes, stereotypies, absent eye contact	no	yes
BRAIN MR																	
First brain MR/age	Normal/6 mo	Normal/4 mo	Normal/5 d	Normal/1 y	Normal/21 d	Normal/3 d	Mild Chiari I/14 d	Tight T2 weighted hyperintensity of the parietal region, cerebellum and brain stem/15 d	Mild cerebral and cerebellar atrophy/3 y	Mild enlargement of lateral ventricle/7 y	Mild cerebral atrophy/6 mo	Mild cerebral atrophy/4 mo	Normal/5 d	Normal/1 y	Normal/21 d	Normal/4 mo	Normal/4 mo
Second brain MR/age	Cerebellar atrophy/6 y	Cerebellar atrophy/3 y	Cerebral atrophy/2 y	Cerebellar atrophy/8 y	Bilateral mesial temporal sclerosis (R > L), mild prominence of cerebellar folia/12 y	No	Mild Chiari I/2 y	n.a.	Mild cerebral and cerebellar atrophy/8 y	Mild enlargement of lateral ventricle/13 y	Diffuse cerebral atrophy/1 y 7 mo	Mild cerebral atrophy/2 y 9 mo	Normal/10 d	Normal/4 y	Normal/2 y	Normal/3 y 4 mo	No

Abbreviations: A, Absences; AS, atonic seizure; ASD, autism spectrum disorder; ASM, anti-seizure medication; AZA, acetazolamide; BG, background activity; CBZ, carbamazepine; CZP, clonazepam; d, days; ES, epileptic spasm; ESM, ethosuximide; F, female; FBTCS, focal to bilateral tonic-clonic seizures; FS, focal seizure; FTS, focal tonic seizure; FU, follow-up; GBP, gabapentin; GTCS, generalized tonic-clonic seizure; GVG, vigabatrin; ID, intellectual disability; KBr, potassium bromide; KD, ketogenic diet; L, left; LEV, levetiracetam; LTG, lamotrigine; M, male; m, months; MS, myoclonic seizure; n.a., not available; NZP, nitrazepam; OXC, oxcarbazepine; PB, phenobarbital; PER, perampanel; PHT, phenytoin; PLP, pyridoxal-5-phosphate; PN, pyridoxine; PRG, pregabalin; R, right; RTG, retigabine; RUF, rufinamide; SE, status epilepticus; SW, spike and wave; TPM, topiramate; TS, tonic seizure; VNS, vagal nerve stimulation; VPA, valproate; y, years; ZNS, zonisamide.

[a]Presumed gonadal mosaicism in unaffected parent.

[b]Inherited from healthy mother (blood leukocyte with a **variant** allele fraction of 11.7% - 11/94 clones).

[c]Inherited from affected father with onset of drug-resistant epilepsy at age 8 mo (blood leukocyte mutant allele fraction of 7% - 10/1479 reads);

[d]Inherited from affected mother who had epilepsy during infancy (blood leukocyte mutant allele fraction of 52% - 178/338 reads).

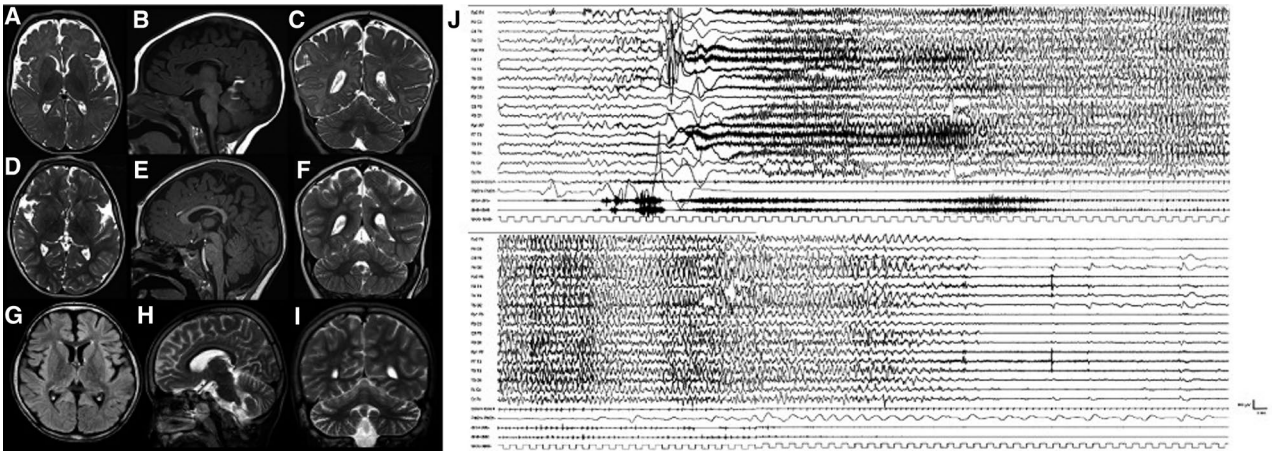

FIGURE 1 Brain MRI of Patients L and I (A-I), and ictal EEG of Patient L (J). Patient L at the age of 2 years 3 months (A-C) and 2 years 7 months (D-F): cerebral atrophy, with enlarged subarachnoid spaces around the frontal and insular lobes, without significant progression of the atrophy. Patient I at the age of 8 years (G-I): mild cerebral and cerebellar atrophy with enlarged subarachnoid spaces around the frontal and insular lobes and cerebellar folia. Ictal EEG of Patient L at the age of 42 days (J). Ictal discharge starts with diffuse bilateral, symmetrical, low-voltage fast activity, increasing in amplitude and decreasing in frequency. The patient has a massive tonic contraction with perioral cyanosis and sialorrhea. Polygraphic recording shows ictal bradycardia at seizure onset for about 5 sconcomitant with the beginning of the tonic phase (see bilateral contraction of upper limb in deltoids). Afterward, the patient appears floppy and pale associated with a brief compensatory tachycardia. The seizure spontaneously ends after 86 s

3.4 | Other neurologic findings

Intellectual disability (ID) was severe in seven patients, moderate in seven, and mild in one; nine were nonverbal. Of 14 patients older than 18 months, nine walked independently, whereas six of them were ataxic and five never walked. Three patients had cortical visual impairment (Patients A, B, and C), one nystagmus (Patient G). In 14 of 17 patients with neonatal-onset epilepsy, developmental delay was not noted before seizure onset, in the remaining three patients with onset between 4 months and 3 years and 5 months the development was reported as normal before seizure onset.

3.5 | Brain MR findings

Brain MRI was normal in 11 of 15 patients who had imaging within the first year of life. The remaining four patients had a mild Chiari I malformation (Patient G); T2-weighted hyperintensity of the parietal areas, cerebellum, and brainstem (Patient H); and mild cerebral atrophy (Patients K, L) (Figure 1). During follow-up, in four patients, MRI remained normal. Five patients developed cerebellar atrophy and one of them also bilateral mesial temporal sclerosis. Two patients (Patients I, J) had their first brain MRI later in life, between the ages of 3 and 7 years, revealing mild cerebral and cerebellar atrophy (Figure 1).

Overall 9 of 17 patients (52.9%) had cerebral (n = 5) and/or cerebellar (n = 5) atrophy on brain MRI, which was progressive in 6 patients.

3.6 | Genotype-phenotype correlation

Seizure onset was before the age of 42 days in all 14 patients with the p.Arg114His variant (13 within 30 days, and 10 of them within 8 days of life). Seizure onset was at 4 months in both children with the p.Gly112Ser variant (Patients P-Q). Patient I with *FHF1* duplication developed seizures at age 3 years 5 months.

Twelve of 14 patients (85.7%) with the p.Arg114His variant had moderate to severe ID, while the two patients with the p.Arg114His mutation had normal development (Patient P) and one moderate ID (Patient O). Brain MRI abnormalities were recurrent in patients with p.Arg114His variant, whereas both patients with p.Gly112Ser variant had normal brain MRI.

4 | DISCUSSION

We present a large cohort of individuals with *FHF1*-DEE, incorporating 12 previously published case reports, and refine the phenotypic spectrum.

FHFs are small cytosolic proteins that interact with the cytoplasmic tails of voltage-gated sodium channels ($Na_v1.6$), encoded

by *SCN8A*, and promote excitability by elevating the voltage dependence of neuronal sodium channel fast inactivation[9].

Siekierska et al were the first ever to link the *FHF1* gene to an early onset epileptic encephalopathy, also demonstrating a gain-of-function effect of the FHF1 mutant protein (p.Arg114His)[9]. The prevalence of *FHF1*-DEE has not been estimated; however, it seems to be rare, given that only 12 patients have been reported since 2016[5-11] and we collected only 5 additional new patients. Of interest, complex chromosomal rearrangements involving 9p deletion and the 3q28q29 microduplication involving *FHF1* have been described recently in 16 patients. However, only 3 of 16 patients had epilepsy,[14] far fewer than patients with *FHF1* missense variants.

As reported previously, the *FHF1* p.Arg114His missense mutation is a hotspot locus and acts in a gain-of-function fashion on voltage-gated sodium channels[9]. A gain-of-function mechanism has also been invoked for the p.Gly112Ser variant and *FHF1* duplication[10,14].

In terms of genotype-phenotype correlation, we found that patients with the recurrent p.Arg114His missense mutation had an earlier epilepsy onset, mainly in the neonatal period, with severe developmental impairment and psychiatric features. Patients with the p.Gly112Ser variant and the *FHF1* duplication, had later epilepsy onset, after the age of 4 months, and a milder clinical phenotype in terms of development. Conversely, there were no significant differences between the two missense variants, in terms of seizure semiology. Evolution to SE was frequent and, in about one-third of patients, SE was recurrent during life.

The clinical outcome of patients with *FHF1* pathogenic variants was poor in most of the patients. ID was moderate or severe in 76.47% of patients, and a developmental regression was observed in 47.1%. Patients with the *FHF1* p.Arg114His mutation had even poorer outcome, with a moderate-severe ID in 78.6% of cases, whereas patients with the p.Gly112Ser mutation had normal development or moderate ID. Because of neonatal seizure onset, in most of the patients it was difficult to ascertain the role of epilepsy in developmental delay.

The retrospective nature of this study does not allow one to draw any firm conclusions about the efficacy of specific antiseizure medications (ASMs). However, it is worth noting that phenytoin, was effective in six patients (35.3%), confirming what was observed in single cases[10,11]. The efficacy of sodium channel blocking drugs, such as phenytoin, could be explained by the interaction between FHF1 and the $Na_V1.6$ sodium channel subunit, encoded by *SCN8A*. In *SCN8A*-DEE, epilepsy is responsive to sodium channel blockers[15-16].

Brain MRI showed no specific abnormalities at seizure onset, whereas 52.9% of patients had cerebral and/or cerebellar atrophy on brain MRI during follow-up, which was progressive in six patients, mostly in patients with p.Arg114His mutation.

The overall mortality (11.8%) is high compared with other epilepsies, but comparable with *SCN8A*-DEE and *SCN2A*-DEE[17]. Two patients in our cohort died during infancy: one died during SE, whereas the other of unknown cause, consistent with possible sudden unexpected death in epilepsy (SUDEP). Both of them carried the recurrent p.Arg114His mutation, which is associated with the poorer phenotype.

With regard to inheritance, as observed in other gene-related DEEs[18], the majority of mutations arise de novo, although it is remarkable that in 29.5% of cases, somatic or gonadal mosaicism was reported in a parent. Because of the possibility of undetected gonadal or somatic mosaicism, it is critical to offer reproductive counseling to couples who have a child with *FHF1*-DEE regardless of whether the disease-causing mutation has been detected in a parent[18].

When *FHF1*-DEE is compared with the other neonatal-onset genetic DEEs (such as *SCN2A, KCNQ2,* and *SCN8A*), they share a high occurrence of tonic seizures. Cerebellar atrophy has been reported previously in DEEs associated with mutations in several other genes including those encoding voltage-gated sodium channel subunits such as *SCN8A*[15]. Among other early onset DEEs, *SCN8A*-DEE seems to be the condition with which *FHF1*-DEE shares more features, such as seizure type, response to drugs, and cerebellar atrophy and these common features might be due to the interaction between *FHF1* and the $Na_V1.6$ sodium channel subunit, encoded by *SCN8A*.

Overall, we described the phenotype of 17 patients with *FHF1*-DEE collected through an international multicenter collaboration. Most of the patients presented with drug-resistant epilepsy and, even if most of the drugs were not effective, a slight improvement was reached with the use of sodium channel blockers. EEG showed mainly multifocal abnormalities, not specific for this condition.

Our findings expand and refine the clinical, EEG, and imaging phenotype of patients with *FHF1*-DEE, which is characterized by an early-onset epilepsy with tonic seizures, associated with moderate to severe ID and psychiatric features. Further experimental studies are needed to shed light on the underlying pathophysiology of *FHF1*-DEE in order to inform management and treatment, define the natural history, and prognostic factors for outcome.

ACKNOWLEDGMENTS

We would like to thank the patients and their families for participation in this study.

CONFLICTS OF INTEREST

The authors have no conflicts of interest to report. We confirm that we have read the Journal's position on issues involved in ethical publication and affirm that this report is consistent with those guidelines.

ORCID

Marina Trivisano https://orcid.org/0000-0002-9841-8581
Elizabeth Bebin https://orcid.org/0000-0002-6725-2814
Gaetan Lesca https://orcid.org/0000-0001-7691-9492
Lieven Lagae https://orcid.org/0000-0002-7118-0139
Federico Vigevano https://orcid.org/0000-0001-7513-0051
Laurent Villard https://orcid.org/0000-0001-6657-5008
Nicola Specchio https://orcid.org/0000-0002-8120-0287

REFERENCES

1. Scheffer IE, Berkovic S, Capovilla G, Connolly MB, French J, Guilhoto L, et al. ILAE classification of the epilepsies: position paper of the ILAE commission for classification and terminology. Epilepsia. 2017;58:512–21.
2. Trivisano M, Specchio N. What are the epileptic encephalopathies? Curr Opin Neurol. 2020;33:179–84. https://doi.org/10.1097/WCO.
3. Rochtus A, Olson HE, Smith L, Keith LG, El Achkar C, Taylor A, et al. Genetic diagnoses in epilepsy: the impact of dynamic exome analysis in a pediatric cohort. Epilepsia. 2020;61:249–58.
4. Symonds JD, McTague A. Epilepsy and developmental disorders: next generation sequencing in the clinic. Eur J Paediatr Neurol. 2020;24:15–23.
5. Takeguchi R, Haginoya K, Uchiyama Y, Fujita A, Nagura M, Takeshita E, et al. Two Japanese cases of epileptic encephalopathy associated with an FGF12 mutation. Brain Dev. 2018;40:728–32.
6. Villeneuve N, Abidi A, Cacciagli P, Mignon-Ravix C, Chabrol B, Villard L, et al. Heterogeneity of FHF1 related phenotype: novel case with early onset severe attacks of apnea, partial mitochondrial respiratory chain complex II deficiency, neonatal onset seizures without neurodegeneration. Eur J Paediatr Neurol. 2017;21:783–6.
7. Guella I, Huh L, McKenzie MB, Toyota EB, Bebin EM, Thompson ML, et al. De novo FGF12 mutation in 2 patients with neonatal-onset epilepsy. Neurol Genet. 2016;2:e120.
8. Al-Mehmadi S, Splitt M, Ramesh V, DeBrosse S, Dessoffy K, Xia F, et al. FHF1 (FGF12) epileptic encephalopathy. Neurol Genet. 2016;2:e115.
9. Siekierska A, Isrie M, Liu Y, Scheldeman C, Vanthillo N, Lagae L, et al. Gain-of-function FHF1 mutation causes early-onset epileptic encephalopathy with cerebellar atrophy. Neurology. 2016;86:2162–70.
10. Shi RM, Kobayashi T, Kikuchi A, Sato R, Uematsu M, An K, et al. Phenytoin-responsive epileptic encephalopathy with a tandem duplication involving FGF12. Neurol Genet. 2017;3:e133.
11. Paprocka J, Jezela-Stanek A, Koppolu A, Rydzanicz M, Kosińska J, Stawiński P, et al. FGF12p.Gly112Ser variant as a cause of phenytoin/phenobarbital responsive epilepsy. Clin Genet. 2019;96:274–5.
12. Epilepsy Genetics Initiative. The epilepsy genetics initiative: systematic reanalysis of diagnostic exomes increases yield. Epilepsia. 2019;60:797–806.
13. Fisher RS, Cross JH, French JA, Higurashi N, Hirsch E, Jansen FE, et al. Operational classification of seizure types by the international league against epilepsy: position paper of the ILAE commission for classification and terminology. Epilepsia. 2017;58:522–30.
14. Oda Y, Uchiyama Y, Motomura A, Fujita A, Azuma Y, Harita Y, et al. Entire FGF12 duplication by complex chromosomal rearrangements associated with West syndrome. J Hum Genet. 2019;64:1005–14.
15. Gardella E, Marini C, Trivisano M, Fitzgerald MP, Alber M, Howell KB, et al. The phenotype of SCN8A developmental and epileptic encephalopathy. Neurology. 2018;91(12):e1112–e1124.
16. Oyrer J, Maljevic S, Scheffer IE, Berkovic SF, Petrou S, Reid CA. Ion channels in genetic epilepsy: from genes and mechanisms to disease-targeted therapies. Pharmacol Rev. 2018;70:142–73.
17. Berg T, Nickels K, Wirrel C, Geerts AT, Callenbach PM, Arts WF, et al. Mortality risk in new-onset childhood epilepsy. Pediatrics. 2013;132(1):124–31.
18. Myers CT, Hollingsworth G, Muir AM, Schneider AL, Thuesmunn Z, Knupp A, et al. Parental mosaicism in "De Novo" epileptic encephalopathies. N Engl J Med. 2018;378:1646–8.

How to cite this article: Trivisano M, Ferretti A, Bebin E, et al. Defining the phenotype of *FHF1* developmental and epileptic encephalopathy. *Epilepsia*. 2020;00:1–8. https://doi.org/10.1111/epi.16582