

**RESEARCH ARTICLE**

The phenotype of Sotos syndrome in adulthood: A review of 44 individuals

Alison Foster^{1,2}  | Anna Zachariou³ | Chey Loveday³ | Tazeen Ashraf⁴ |
Edward Blair⁵ | Jill Clayton-Smith^{6,7} | Huw Dorkins⁸ | Alan Fryer⁹ | Blanca Gener¹⁰ |
David Goudie¹¹ | Alex Henderson¹² | Melita Irving⁴ | Shelagh Joss¹³ |
Vaughan Keeley¹⁴ | Nayana Lahiri¹⁵ | Sally Ann Lynch¹⁶ | Sahar Mansour^{15,17} |
Emma McCann⁹ | Jenny Morton² | Nicole Motton¹⁸ | Alexandra Murray¹⁹ |
Katie Riches¹⁴ | Deborah Shears⁵ | Zornitza Stark^{20,21} | Elizabeth Thompson^{22,23} |
Julie Vogt² | Michael Wright¹² | Trevor Cole² | Katrina Tatton-Brown^{3,15,17}

¹University of Birmingham, Institution of Cancer and Genomic Sciences, Birmingham, UK

²West Midlands Regional Clinical Genetics Service and Birmingham Health Partners, Birmingham Women and Children's NHS Foundation Trust, Birmingham, UK

³Division of Genetics and Epidemiology, Institute of Cancer Research, London, UK

⁴Department of Clinical Genetics, Guy's and St Thomas' NHS Foundation Trust, London, UK

⁵Oxford Centre for Genomic Medicine, Oxford University Hospitals NHS Foundation Trust, Oxford, UK

⁶Division of Evolution and Genomic Sciences, School of Biological Sciences, Faculty of Biology, Medicine and Health, University of Manchester, Manchester, UK

⁷Manchester Centre for Genomic Medicine, St Mary's Hospital, Manchester University NHS Foundation Trust, Health Innovation Manchester, Manchester, UK

⁸Leicester Royal Infirmary, University Hospitals of Leicester NHS Trust, Leicester, UK

⁹Department of Clinical Genetics, Liverpool Women's NHS Foundation Trust, Liverpool, UK

¹⁰Department of Genetics, Cruces University Hospital, Biocruces Bizkaia Health Research Institute, Barakaldo, Spain

¹¹East of Scotland Regional Genetics Service, Ninewells Hospital and Medical School, Dundee, UK

¹²Northern Genetics Service, The Newcastle upon Tyne Hospitals NHS Foundation Trust, Newcastle upon Tyne, UK

¹³West of Scotland Regional Genetics Service, Laboratory Medicine Building, Queen Elizabeth University Hospital, Glasgow, UK

¹⁴University Hospitals of Derby and Burton NHS Foundation Trust, Derby, UK

¹⁵South West Thames Regional Genetics Service, St George's University Hospitals NHS Foundation Trust, London, UK

¹⁶Department of Clinical Genetics, Temple Street Children's University Hospital, Dublin, Ireland

¹⁷St George's University of London, London, UK

¹⁸West Midlands Regional Genetics Service, Birmingham Women's Hospital, Birmingham, UK

¹⁹All Wales Medical Genomics Service, University Hospital of Wales, Cardiff, UK

²⁰Victorian Clinical Genetics Services, Murdoch Children's Research Institute, Melbourne, Australia

²¹Department of Paediatrics, University of Melbourne, Melbourne, Australia

²²SA Clinical Genetics Service, Women's and Children's Hospital, Adelaide, South Australia, Australia

²³Faculty of Health and Medical Sciences, University of Adelaide, Adelaide, South Australia

Correspondence

Katrina Tatton-Brown, Division of Genetics and Epidemiology, Institute of Cancer Research, London, UK.
Email: k.tattonbrown@nhs.net

Abstract

Sotos syndrome is an overgrowth-intellectual disability (OGID) syndrome caused by *NSD1* pathogenic variants and characterized by a distinctive facial appearance, an intellectual disability, tall stature and/or macrocephaly. Other associated clinical features include scoliosis, seizures, renal anomalies, and cardiac anomalies. However,

Funding information

Child Growth Foundation, Grant/Award Number: GR01/13; National Institute for Health Research; Wellcome Trust, Grant/Award Number: 100210

many of the published Sotos syndrome clinical descriptions are based on studies of children; the phenotype in adults with Sotos syndrome is not yet well described. Given that it is now 17 years since disruption of *NSD1* was shown to cause Sotos syndrome, many of the children first reported are now adults. It is therefore timely to investigate the phenotype of 44 adults with Sotos syndrome and *NSD1* pathogenic variants. We have shown that adults with Sotos syndrome display a wide spectrum of intellectual ability with functioning ranging from fully independent to fully dependent. Reproductive rates are low. In our cohort, median height in adult women is +1.9 SD and men +0.5 SD. There is a distinctive facial appearance in adults with a tall, square, prominent chin. Reassuringly, adults with Sotos syndrome are generally healthy with few new medical issues; however, lymphedema, poor dentition, hearing loss, contractures and tremor have developed in a small number of individuals.

KEYWORDS

adult phenotype, overgrowth-intellectual disability syndrome, Sotos syndrome

1 | INTRODUCTION

Sotos syndrome (OMIM #117550) was first described in 1964 by Dr Juan Sotos (Sotos, Dodge, Muirhead, Crawford, & Talbot, 1964) and has an estimated incidence of 1 in 14,000 live births (Tatton-Brown, Cole, & Rahman, 2004). The cardinal clinical features of Sotos syndrome include a characteristic facial appearance, an intellectual disability and overgrowth (defined as height and/or head circumference at least two standard deviations above the mean, $\geq +2.0$ SD; Cole & Hughes, 1994; Tatton-Brown et al., 2005). Most easily recognized in early childhood, the classical facial appearance consists of a tall forehead, frontal-temporal balding, downslanting palpebral fissures, malar flushing, long and narrow face, narrow jaw and a tall, broad chin (Allanson & Cole, 1996). Other major clinical associations, reported in at least 15% of individuals, include scoliosis, seizures, renal anomalies, and cardiac anomalies (Tatton-Brown et al., 2005). The majority of individuals have advanced bone age (Cole & Hughes, 1994). Abnormalities on brain MRI scan, most frequently ventriculomegaly, are common (Schaefer, Bodensteiner, Buehler, Lin, & Cole, 1997).

Sotos syndrome is caused by *NSD1* heterozygous pathogenic variants (Kurotaki et al., 2002). *NSD1* is located at chromosome region 5q35 and encodes a histone methyltransferase that catalyzes the transfer of methyl groups to lysine residues of histone tails: more specifically lysine residue 36 of histone H3 (H3K36) and less frequently lysine residue 20 of histone H4 (H4K20) (Rayasam et al., 2003). These methylation marks are most frequently associated with transcriptional activation but can be associated with repression depending on the cellular context (Cao et al., 2002; Huang et al., 1998).

Although Sotos syndrome is a well-characterized overgrowth-intellectual disability (OGID) syndrome, the vast majority of studies have focused on the childhood clinical presentation and there are limited data on the evolution of the phenotype into adulthood (Fickie et al., 2011). In particular, there is debate around the final adult height

and concerns about reproductive outcomes, new or progressive health problems in adulthood and experiences of day-to-day living. As it is 17 years since *NSD1* haploinsufficiency was shown to cause Sotos syndrome, many children diagnosed through genetic testing have now reached adulthood. It is therefore timely to undertake a study on 44 adults to clarify the adult presentation and optimize individual care for Sotos syndrome.

2 | METHODS

2.1 | Editorial policies and ethical considerations

The study was approved by the London Multicenter Ethics Committee (MREC01/02/44 and 05/MRE02/17). Informed consent for participating in the study was obtained for all participants.

2.2 | Case series

Forty-four adults with Sotos syndrome and a confirmed *NSD1* pathogenic variant were recruited including 17 males and 27 females. The age range of study participants was 18–48 years with a mean age of 30 years (Table S1).

Twenty-six of the 44 individuals had previously been included, as children, in a study to clarify genotype–phenotype relationships in Sotos syndrome (Tatton-Brown et al., 2005). These individuals, now older than 18 years, were re-contacted to ask for their continued participation in the adult Sotos study. Eighteen individuals were identified through testing in the diagnostic laboratories within and outside of the UK.

Phenotype data were obtained through a clinic meeting (23 individuals) or a standardized clinical proforma-completed either by their Clinical Geneticist or individual/family member respectively (21 individuals). Clinical photographs with accompanying consent for publication were requested from all individuals and received from 17 families.

3 | RESULTS

The majority of study participants enjoyed good health. However, notable themes in adulthood included a variable intellectual disability; specific behavioral issues; differences in male and female growth patterns; puberty and reproduction and new and evolving medical problems. The full range of adult and childhood-onset clinical issues, growth, and spectrum of intellectual disability is detailed in supplementary Table S1.

3.1 | Intellectual disability

The degree of intellectual disability was variable within the cohort, with eight individuals (18%) reported to have normal learning while 17 (39%) had a mild intellectual disability, 12 (27%) a moderate intellectual disability and seven (16%) a severe intellectual disability (Table 1, Figure 1).

All individuals reported to have normal learning were employed in a range of jobs including as a carer, barber, and sales clerk or in vocational training courses including information technology, nursing and business studies (Figure 1).

Nearly all (15/17, 88%) individuals with a mild intellectual disability were completely independent in self-caring (washing, brushing teeth and dressing, Figure 1). 59% (10/17) felt unable or did not want to live away from the support of their families. Managing money and finances was an

TABLE 1 Learning, behavior, new medical issues, and complications of known Sotos syndrome clinical associations described in at least two adults with Sotos syndrome

Clinical feature	Number of affected patients	Percentage of affected patients
Intellectual disability		
None	8	18%
Mild	17	39%
Moderate	12	27%
Severe	7	16%
Behavior		
Autistic spectrum disorder	9	20%
Anger/aggression	7	16%
Anxiety	6	14%
New medical issues		
Aortic dilatation	4	9%
Contractures	4	9%
Tremor	3	7%
Lymphedema	3	7%
Dental issues	7	16%
New complications of known medical associations		
Chronic pain following scoliosis surgery	3	7%
Long-term complications of congenital renal anomalies	3	7%

area of difficulty mentioned by 24% (4/17). Most (14/17, 82%) individuals with a mild intellectual disability were employed or engaged in vocational training in diverse fields including retail, painting/decorating, waitressing, health and social care, air stewarding and cleaning.

Only five (5/12, 42%) individuals with a moderate intellectual disability were independent in self-caring (Figure 1) and two were in supported employment (shop assistant and office assistant). None of the adults with severe intellectual disability were self-caring or in employment; seven attended special educational needs colleges or day care and one was receiving 24 hr care.

3.2 | Behavior

Nine adults (20%), all with a moderate or severe intellectual disability, had a diagnosis of autistic spectrum disorder. Other adult-onset behavioral/psychiatric issues included anger/aggression (seven individuals) and anxiety (manifesting as panic attacks and/or social avoidance [six individuals]). One adult with anxiety had co-existing depression and continued to take anti-psychotic medication commenced for an episode of psychosis at the age of 13.

3.3 | Growth

3.3.1 | Female adult growth

Female adult height ranged from -0.1 to $+6.0$ SD, with a median of $+1.9$ SD; weight ranged from -1.4 to $+3.8$ SD with a median of $+1.7$ SD and BMI ranged from -1.1 to $+3.8$ SD with a median of $+1.2$ SD. The head circumference ranged from $+0.8$ to $+6.1$ SD with a median of $+2.7$ SD (Figure 2).

3.3.2 | Male adult growth

Male adult height ranged from -1.5 to $+3.2$ SD, with a median $+0.5$ SD; weight ranged from -1.3 to $+3.1$ SD with a median $+1.0$ SD and BMI ranged from -1.0 to $+2.6$ SD with a median of $+1.2$ SD (height and BMI data excluded one adult male with severe progressive scoliosis awaiting surgery [height -3.0 SD]). The head circumference ranged from $+0.7$ to $+3.9$ SD with a median of $+2.4$ SD (Figure 2).

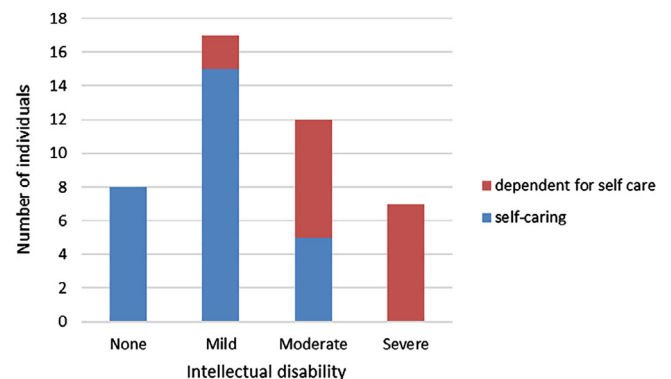


FIGURE 1 The range of intellectual disability related to ability to self-care in adults with Sotos syndrome

3.4 | Facial appearance

The facial appearance in adults with Sotos syndrome remained distinctive with downslanting palpebral fissures, high hairline and tall, broad chin (Figure 3b). However, characteristic facial features of children with Sotos syndrome such as malar flushing and narrow jaw line were not evident in adulthood (Figure 3a).

3.5 | Puberty and reproductive issues

Menarche ranged from 7 to 16 years with a median age of 13 years, comparable to the median age of 12.9 years in girls in the general UK

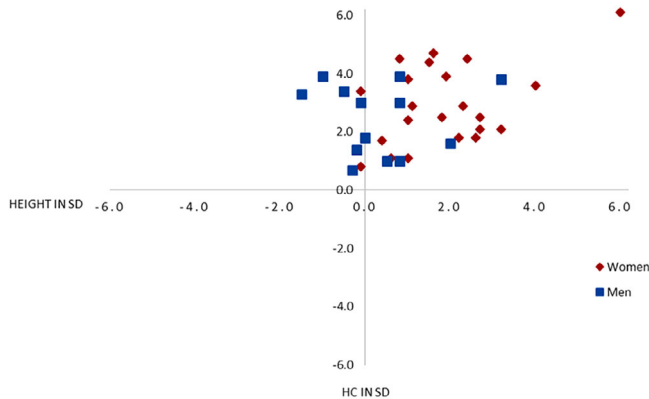


FIGURE 2 The range of height and head circumference in standard deviation (SD) in women and men with Sotos syndrome

population (Whincup, Gilg, Odoki, Taylor, & Cook, 2001). One girl required hormonal treatment to initiate puberty at the age of 14 years. Given that the onset of male puberty is harder to define, we used the age at which the voice broke as a proxy: this ranged from 11 to 17 years with a median age of 14 years. This is similar to the UK population, with the change in male voice in puberty occurring between Tanner Stage 3 at a mean age of 12.9 years and Tanner Stage 4 at mean age of 13.8 years (Harries, Walker, Williams, Hawkins, & Hughes, 1997; Marshall & Tanner, 1970).

Four women in our cohort had children. The first had two children, neither of whom had Sotos syndrome. The second was diagnosed with Sotos syndrome in adulthood following the diagnosis in her monozygotic twins. She also had an unaffected child. The third conceived an affected child through in vitro fertilization for prolonged infertility and the fourth had four children, one of whom had inherited the *NSD1* alteration.

One man was known to have a low sperm count and did not have children. No other individuals reported planning to have children or infertility issues.

3.6 | Associated medical problems

3.6.1 | New medical problems

In general, adults with Sotos syndrome were healthy with few new medical issues. New medical problems reported in at least two adults included dental problems, hearing loss, aortic dilatation, contractures, lymphedema and tremor.




FIGURE 3 (a) The evolving facial appearance from childhood to adulthood and (B) the adult facial appearance in Sotos syndrome

Dental problems

Dental problems were reported in seven adults (7/44, 16%): soft, worn or crumbling teeth (three individuals); absent and/or abnormal secondary dentition (four individuals) (Table 1).

Hearing loss

Seven adults (7/44, 16%) had hearing loss, two of whom had recurrent ear infections, one with a cholesteatoma diagnosed age 25, one with degenerative changes of the eardrum and three with hearing loss of unspecified cause. Four individuals wore hearing aids.

Aortic dilatation

Four individuals had dilatation of the aortic root or ascending aorta (Table 1). However, in two of these individuals (COG1878 and COG1918) the dilatation had resolved by their 30s/40s and the third individual (COG0622, previously reported by Robertson and Bankier 1999 and Hood et al., 2016) had a mild diffuse non-progressive dilatation of the ascending aorta for which he was treated with prophylactic beta blocker therapy (Hood et al., 2016). The fourth individual (COG2057) was diagnosed with borderline enlargement of the aortic sinus at the age of 47 that was not present on transthoracic echocardiogram at the age of 39. A repeat echocardiogram is planned in 5 years' time to assess for progression.

Contractures

Contractures affected four adults: one individual developed mild contractures of both elbows in adulthood, with no prior history of hypermobility (COG0030); a second developed hip and ankle contractures (with tight tendo-Achilles and hamstrings, COG0588) and two individuals developed bilateral camptodactyly (COG0045 and COG0254, Table 1).

Lymphedema

Three individuals developed lower limb lymphedema in adulthood. One individual (COG2026) initially developed right leg swelling at the age of 32, shortly followed by swelling in the left. On examination, both legs were Stemmers positive and bilateral lymphedema was confirmed by lymphoscintigram. Testing of *FLT4* did not identify a gene variant causative of the lymphedema. The second patient (COG2057) developed bilateral lower limb lymphedema at the age of 21. This was treated with compression stockings and a lymphedema pump 3 hr per day. Whole exome sequencing did not identify a gene variant causative of the lymphedema. The third patient (COG) developed bilateral lymphoedema of the feet age 16. Of note, two of the individuals with lymphoedema (COG2057 and COG0721) also developed pericarditis: COG2057 developed pericarditis complicated by pericardial effusion at the age of 21. No specific cause was identified. She required admission to critical care for 5 days and subsequently developed lymphedema. COG0721 had myopericarditis at the age of 20, 4 years after the onset of lymphedema.

Tremor

Two of the individuals described with camptodactyly (COG0045 and COG0254) also developed progressive essential tremor (Table 1). This impacted their ability to undertake everyday tasks such as eating, drinking, and dressing. One of these individuals was receiving symptomatic treatment with propranolol and clonidine. A third individual (COG2057) developed a progressive tremor in her early 30s with no current impact on function.

3.6.2 | New complications of known Sotos syndrome medical associations

Scoliosis

Scoliosis is one of the most common Sotos syndrome medical problems, previously reported in one third of individuals (Tatton-Brown et al., 2005). Over half the adults (24/44, 55%) had scoliosis and/or kyphosis. All except one individual were diagnosed before age 16. Eleven individuals with scoliosis (11/24, 46%) required surgery. Three adults with surgically treated scoliosis developed severe chronic pain: the first needed a wheelchair to walk more than 100 m and was being managed by orthopedics with joint injections; the second was receiving treatment with amitriptyline and the third adult had chronic leg pain, paresthesia, and breathlessness and was being managed by the neurosurgeons and pain team (Table 1). All three had normal intellect or a mild intellectual disability and had left employment or training due to chronic pain.

Renal anomalies

A minority of individuals (8/44, 18%) had congenital renal anomalies, including combinations of hydronephrosis, pelvi-ureteric junction obstruction, hydroureters, renal agenesis, duplicated ureter, and/or posterior urethral valves. Two individuals with congenital renal anomalies developed hypertension: one in his early 20s with an absent right kidney and left sided hydronephrosis and hydroureter, and the other in her late 40s with a duplicated left ureter (surgically repaired) and recurrent urinary tract infections). In addition, one individual with posterior urethral valves required a long-term indwelling catheter (Table 1). No individuals in the current study had chronic renal impairment.

4 | DISCUSSION

The results of this study describe important outcomes for adults with Sotos syndrome with regards to features of adult life including employment, independent living, and reproductive status as well as growth parameters, long-term medical problems, and any evolving medical issues.

There was a wide spectrum of independence, ability to self-care and employment status in our series. Of particular note, eight individuals were reported to have normal intellect, broadening our perception of the potential achievements of a small proportion of individuals with Sotos syndrome. Two of these individuals, including one adult who lived abroad for 2 years to attend a business course in a second language, had struggled academically in mainstream school. Autistic

spectrum disorder was present in over 20% of adults with Sotos syndrome and may represent an area where additional support would be of benefit. Anxiety was also a key issue for some adults and increased recognition and support in this area may improve quality of life and independence for these individuals.

In contrast to childhood data but consistent with another study on adult Sotos syndrome (Fickie et al., 2011), our study identified a difference in the final height attained by men and women, with women frequently remaining tall (median height + 1.9 SD) in adulthood while men are more likely to have a height within the normal range (median height + 0.5 SD). One explanation for this male/female discrepancy would be if puberty were delayed in girls and/or early in boys. There was no evidence for this in the current series where puberty occurred within the normal range in both sexes. We also did not identify a difference in the incidence of untreated scoliosis between men and women, which might explain the discrepancy in excess height. However, we must consider that data on parental heights are not available which would enable a more accurate assessment of excessive height for each individual. It is possible that by chance female individuals had taller than average parents and/or male individuals had shorter than average parents, influencing their target height.

Reproductive rates in our study were low. However, as this was a cohort of young adults with an average age of 30, it is possible that other individuals will go on to have children in the future. Fertility issues were reported in two individuals.

Reassuringly, this study did not highlight many new or evolving Sotos syndrome medical problems. Primary bilateral lower limb lymphedema developed in three individuals in our study, two of whom interestingly also developed pericarditis (chylous pericardial effusion is a known association of lymphedema). An additional adult with primary lymphedema has been reported in the literature (McClelland, Burgess, Crock, & Goel, 2016). In two of our cases and the case in the literature, sequencing of primary lymphedema genes did not identify causative gene alterations. It has been postulated that dysregulation of the MAPK/ERK signaling cascade is responsible for both Sotos syndrome and primary lymphedema (McClelland et al., 2016). However, until further functional studies and/or individuals with both diagnoses are identified, we will remain uncertain whether lymphedema is rare association of Sotos syndrome or a coincidental finding.

Of note, four study participants were reported to have a non-progressive aortic dilatation. In two of these individuals the dilatation appeared to resolve. In addition, as there are no published reports of morbidity or mortality related to aortic dilatation in individuals with Sotos syndrome, we therefore do not recommend routine echocardiograms screening for aortic dilatation.

One potentially new and important finding is that two adults had very similar patterns of progressive camptodactyly developing in teenage years followed by the appearance of a progressive bilateral tremor at the age of 20. Both affected individuals were unable to perform fine motor tasks important for activities of daily living. As only two adults had these symptoms it is not possible to be certain whether these findings were related to Sotos syndrome, but it is a distinctive and rare pattern that may constitute a new complication of this

condition in adulthood. Another individual in our study, and another adult with Sotos in the literature (McClelland et al., 2016) developed a tremor without camptodactyly, suggesting that tremor may be an independent association of Sotos syndrome in adulthood.

Scoliosis remained an issue for a small number of individuals who had chronic pain. The development of a cholesteatoma in one individual and degenerative changes of the ear drum in another suggests that specific enquiry should be made about new onset hearing loss when reviewing adults with Sotos syndrome in the clinic. Attendance at routine dental check-ups is advised, as is regular blood pressure measurement to monitor for hypertension, particularly if an individual has had a congenital renal anomaly.

Of note and given previous suggestions that Sotos syndrome may be associated with an increased tumor susceptibility (Lapunzina, 2005), none of the individuals developed tumors in adulthood. Taken together with the now widely reported very low absolute risk of tumors in childhood, we conclude that there is little evidence to support increased tumor surveillance in Sotos syndrome.

The current study has helped to clarify the clinical presentation of Sotos syndrome in adulthood. However, there remain unanswered questions. For instance, it is still not clear whether there are infertility/reproductive issues in Sotos syndrome that may account for so few families/familial cases. In addition, there are limited data on the natural history of the aortic dilatation. Finally, while this is a study into adulthood, only 19 individuals were >30 years old and only seven were >40 years old. We therefore still do not know whether additional clinical problems develop in late adulthood. We will continue to follow the current cohort of individuals as they grow older to address these queries and provide information for individual and families as well as the health care professionals who are involved in transition care of individuals with Sotos syndrome.

ACKNOWLEDGMENTS

We thank the patients and families for their active participation in this study and the clinicians that recruited them. This research was supported by the Wellcome Trust (100210), the Child Growth Foundation (GR01/13), the Institute of Cancer Research, and the NIHR Rare Diseases Translational Research Collaboration.

CONFLICT OF INTERESTS

The authors declare that they have no conflict of interest.

WEB RESOURCES

Mendelian Inheritance In Man, www.omim.org

ORCID

Alison Foster  <https://orcid.org/0000-0002-0216-3909>

REFERENCES

- Allanson, J. E., & Cole, T. R. P. (1996). Sotos syndrome: Evolution of facial phenotype subjective and objective assessment. *American Journal of Medical Genetics*, 65, 13–20.
- Cao, R., Wang, L., Wang, H., Xia, L., Erdjument-Bromage, H., Tempst, P., ... Zhang, Y. (2002). Role of histone H3 lysine 27 methylation in polycomb-group silencing. *Science*, 298, 1039–1043. <https://doi.org/10.1126/science.1076997>
- Cole, T. R., & Hughes, H. E. (1994). Sotos syndrome: A study of the diagnostic criteria and natural history. *Journal of Medical Genetics*, 31, 20–32. <https://doi.org/10.1136/JMG.31.1.20>
- Fickie, M. R., Lapunzina, P., Gentile, J. K., Tolkoff-Rubin, N., Kroshinsky, D., Galan, E., ... Lin, A. E. (2011). Adults with Sotos syndrome: Review of 21 adults with molecularly confirmed NSD1 alterations, including a detailed case report of the oldest person. *American Journal of Medical Genetics, Part A*, 155, 2105–2111. <https://doi.org/10.1002/ajmg.a.34156>
- Harries, M. L., Walker, J. M., Williams, D. M., Hawkins, S., & Hughes, I. A. (1997). Changes in the male voice at puberty. *Archives of Disease in Childhood*, 77, 445–447. <https://doi.org/10.1136/adc.77.5.445>
- Hood, R. L., Mcgillivray, G., Hunter, M. F., Roberston, S. P., Bulman, D. E., Boycott, K. M., ... Dymont, D. (2016). Severe connective tissue laxity including aortic dilatation in Sotos syndrome. *American Journal of Medical Genetics, Part A*, 170, 531–535. <https://doi.org/10.1002/ajmg.a.37402>
- Huang, N., vom Baur, E., Garnier, J. M., Lerouge, T., Vonesch, J. L., Lutz, Y., ... Losson, R. (1998). Two distinct nuclear receptor interaction domains in NSD1, a novel SET protein that exhibits characteristics of both corepressors and coactivators. *The EMBO Journal*, 17, 3398–3412. <https://doi.org/10.1093/emboj/17.12.3398>
- Kurotaki, N., Imaizumi, K., Harada, N., Masuno, M., Kondoh, T., Nagai, T., ... Matsumoto, N. (2002). Haploinsufficiency of NSD1 causes Sotos syndrome. *Nature Genetics*, 30, 365–366. <https://doi.org/10.1038/ng863>
- Lapunzina, P. (2005). Risk of tumorigenesis in overgrowth syndromes: A comprehensive review. *American Journal of Medical Genetics, Part C*, 137C, 53–71. <https://doi.org/10.1002/ajmg.c.30064>
- Marshall, W. a., & Tanner, J. M. (1970). Variations in the pattern of pubertal changes in boys. *Archives of Disease in Childhood*, 45, 13–23. <https://doi.org/10.1136/adc.45.239.13>
- McClelland, J., Burgess, B., Crock, P., & Goel, H. (2016). Sotos syndrome: An unusual presentation with intrauterine growth restriction, generalised lymphedema, and intention tremor. *American Journal of Medical Genetics, Part A*, 170A, 1064–1069. <https://doi.org/10.1002/ajmg.a.37535>
- Rayasam, G. V., Wendling, O., Angrand, P. O., Mark, M., Niederreither, K., Song, L., ... Losson, R. (2003). NSD1 is essential for early post-implantation development and has a catalytically active SET domain. *EMBO Journal*, 22, 3153–3163. <https://doi.org/10.1093/emboj/cdg288>
- Robertson, S., & Bankier, A. (1999). Sotos syndrome and cutis laxa. *Journal of Medical Genetics*, 36, 51–56.
- Schaefer, G. B., Bodensteiner, J. B., Buehler, B. A., Lin, A., & Cole, T. R. P. (1997). The neuroimaging findings in Sotos syndrome. *American Journal of Medical Genetics*, 68, 462–465.
- Sotos, J. F., Dodge, P. R., Muirhead, D., Crawford, J. D., & Talbot, N. B. (1964). Cerebral gigantism in childhood--A syndrome of excessively rapid growth with acromegalic features and a nonprogressive neurologic disorder. *The New England Journal of Medicine*, 271, 109–116. <https://doi.org/10.1056/NEJM196407162710301>
- Tatton-Brown, K., Cole, T. R. P., & Rahman, N. (2004). Sotos syndrome. In M. P. Adam, H. H. Ardinger, R. A. Pagon et al., (Eds.). *GeneReviews® [Internet]*. Seattle (WA): University of Washington; 1993–2019. Available from: <https://www.ncbi.nlm.nih.gov/books/NBK1479>
- Tatton-Brown, K., Douglas, J., Coleman, K., Baujat, G., Cole, T. R. P., Das, S., ... Childhood Overgrowth Collaboration, C. O. (2005). Genotype-phenotype associations in Sotos syndrome: An analysis of 266 individuals with NSD1 aberrations. *American Journal of Human Genetics*, 77, 193–204. <https://doi.org/10.1086/432082>
- Whincup, P. H., Gilg, J., Odoki, K., Taylor, S., & Cook, D. (2001). Age of menarche in contemporary British teenagers: Survey of girls born between 1982 and 1986. *British Medical Journal*, 322, 1095–1096. <https://doi.org/10.1136/bmj.322.7294.1095>

SUPPORTING INFORMATION

Additional supporting information may be found online in the Supporting Information section at the end of this article.

How to cite this article: Foster A, Zachariou A, Loveday C, et al. The phenotype of Sotos syndrome in adulthood: A review of 44 individuals. *Am J Med Genet Part C*. 2019;1–7. <https://doi.org/10.1002/ajmg.c.31738>